

Recurrent Spontaneous Pneumothorax of Unknown Etiology in a Young Patient: Case Report

Trelles Hernandez Daniela¹, Barragan Lagunes Isabel², Rodriguez Relingh Kim³, Lopez Vargas Ener Rene⁴, Quinones Martinez Mayra Eyelyn⁵

^{1,2,3,4,5} Instituto Mexicano del Seguro Social, Unidad Médica de Alta Especialidad No. 14, Hospital de Alta Especialidad de Veracruz.

ABSTRACT

Introduction: Spontaneous pneumothorax is defined as the abnormal accumulation of air in the pleural space between the lungs and the chest wall, it occurs without an obvious etiology, such as trauma or iatrogenic causes. Primary spontaneous pneumothorax occurs when there is no history of underlying lung disease, while secondary spontaneous pneumothorax is associated with a history of underlying lung disease; its diagnosis is based on clinical suspicion and can be confirmed with imaging tests.

Case presentation: We present a 17 year old patient who presented spontaneous right pneumothorax, requiring placement of endopleural tube and Heimlich cannula with long stay, discharged for resolution and later relapsing in initial symptomatology one week later, requiring hospital readmission.

Conclusion The recidivant spontaneous pneumothorax in the context of a young patient with clinical characteristics like those of our patient: tall stature, pectus excavatum, hyperlaxity of the integuments and aortic-mitral murmur, gives us high suspicion of a secondary cause, a good clinical history, with particular focus on the maternal-fetal history and a detailed physical examination, are the most useful tools to integrate a diagnosis of connective tissue diseases.

KEYWORDS: Case report, Spontaneous pneumothorax, recurrent spontaneous pneumothorax, Marfan syndrome.

Abbreviations: MFS= Marfan Syndrome, EPS= Endopleural Tube, VATS= Video Assisted Thoracic Surgery.

ARTICLE DETAILS

Published On:
12 August 2023

Available on:
<https://ijmscr.org/>

INTRODUCTION:

Spontaneous pneumothorax refers to the abnormal accumulation of air in the pleural space between the lungs and the chest wall, without an obvious etiology, such as trauma or iatrogenic causes; while primary spontaneous pneumothorax is not associated with an underlying lung disease, secondary spontaneous pneumothorax is associated with multiple diseases (Table 1); its diagnosis is based on clinical suspicion and can be confirmed with imaging tests (1).

MFS is a systemic connective tissue disorder that is inherited in an autosomal dominant pattern with variable penetrance. Although clinically this disease manifests in many different ways, the most life-threatening manifestations are related to cardiovascular complications, however within the pulmonary manifestations spontaneous pneumothorax is the main manifestation of Marfan syndrome, and bullae are frequently seen on radiographic imaging (2).

The irruption of air into the pleura may be secondary to rupture of bullae which are almost always located in the pulmonary apexes where the pleural pressure gradient is higher than at the base and therefore alveolar ruptures are more frequent (3).

Two frequency peaks in the occurrence of spontaneous pneumothorax are observed: the first occurs between the ages of 15-34 years, while the second appears after the age of 55 years. The incidence of primary spontaneous pneumothorax is inaccurate; however, it predominates in the male sex, ranging from 18-28/100,000 cases per year in men and 1.2-6/100,000 in women (3).

The clinical practice guideline of the Spanish society of thoracic surgery on the management of the patient with spontaneous pneumothorax recommends observation, puncture and aspiration until placement of the chest tube (depending on the magnitude of lung collapse) and although

Recurrent Spontaneous Pneumothorax of Unknown Etiology in a Young Patient: Case Report

they recommend smaller diameter tubes, they refer to the use of thick tubes in NES after failure of drainage with thingauge tubes.

Maggiolo & Rubilar (2017), after their clinical study with patient diagnosed with PSN, conclude that, the main objective in these cases is lung re-expansion and its treatment is resolved based on the quantification of pulmonary involvement and the evaluation of the patient's clinical status. Currently, pleurodesis and bulla resection are reserved for after recurrence of pneumothorax (5,6).

Even with adequate treatment, the recurrence rate of spontaneous pneumothorax is relatively high. Some studies estimate a recurrence rate of more than 50%, with the highest risk in the first 30 days, however, the recurrence rate may be less than 5% after VATS with resection of the vesicles/bullae and pleurodesis (1).

CLINICAL CASE PRESENTATION

17-year-old adolescent, product of the second gestation of young parents, apparently healthy, not consanguineous, with normoevolutionary pregnancy and preterm birth, with birth weight of 4000 grams and a height of 54 cm; she has a history of paternal branch of high height, developmental milestones within normal limits, at 6 years of age she reports thinning and at 13 years of age slight scoliosis is detected, history of recurrent laryngotracheitis until 11 years of age, without chronic degenerative disorders.

Sudden onset of pleuritic pain in the right hemithorax and dyspnea accompanied by nonproductive cough while at rest, dyspnea becomes progressive presenting central cyanosis so he goes to the emergency department saturating at 88% and tachypneic, physical examination highlights the height of 1.90cm and weight of 57 kg, Marfanoid habitus, ectomorphic complexion with dolichostenomelia, blue sclerae, long neck, long thorax, pectus excavatum, ipsilateral hypersonic percussion and abolished pulmonary murmur in right hemithorax, protosystolic murmur grade 2 with splitting of the second sound in aortic and mitral focus, long extremities and arachnodactyly, hyperlaxity of the integuments and dermographism, cubitus valgus. Chest X-ray (Figure 1) showed complete right pneumothorax, without mediastinal displacement, endopleural seal was placed and a Heimlich valve was placed without achieving complete resolution of the pneumothorax (Figure 2), the endopleural tube was repositioned in the operating room, achieving pulmonary expansion at 24 hours (Figure 3), with good clinical evolution, so SEP was removed after 10 days of his hospital

stay and he was discharged asymptomatic. Seven days after his discharge he presented the same clinical picture, without repercussions in other hemodynamic parameters, there was evidence of recurrence of pneumothorax (Figure 4) and an endopleural tube and Heimlich valve were placed without achieving pulmonary reexpansion after 26 days, so thoracoscopy was performed, Therefore, thoracoscopy and chemical and mechanical pleurodesis were performed, achieving 80% expansion 5 days after the procedure (Figures 5 and 6), it was decided to place a double anterior and posterior endopleural tube with biopsy (Figures 7 and 8), the evolution continues.

DISCUSSION

Secondary spontaneous pneumothorax is associated with multiple diseases, among which is Marfan syndrome, which is an autosomal dominant disease that causes abnormal formation of connective tissue, which alters its distensibility. It is generally associated with osteoarticular, cardiological and ocular manifestations, less frequently it can affect the respiratory tract. Patients with Marfan syndrome have a 10 times higher risk of presenting pneumothorax than the general population, with an associated prevalence ranging from 4 to 11% (4).

The diagnosis of Marfan syndrome is based on defined clinical criteria (Ghent nosology), described by international expert opinion to facilitate accurate recognition of this syndrome of genetic origin and to improve patient management and counseling. The Ghent criteria comprise a set of major and minor manifestations in different body systems, have proven to be effective since, with the improvement of molecular techniques, it is possible to confirm the diagnosis in more than 95% of patients (5).

The patient described in this case report has phenotypic features found in patients with Marfan syndrome, which in his case has not yet been studied, however, the presence of spontaneous pneumothorax strongly suggests this etiology. Spontaneous pneumothoraces have a high probability of recurrence so the American standard advises that in the first episode, only air drainage through a tube is performed.

Pleurostomy is the standard treatment for pneumothorax with moderate or massive collapse while thoracotomy is the definitive more invasive treatment in those cases not resolved with pleurostomy, if video-assisted thoracoscopy is available, it is the procedure of choice.

ANNEXES

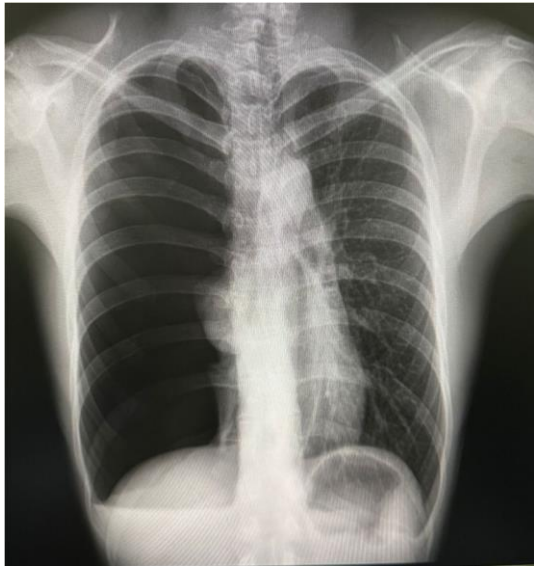

Figure 1

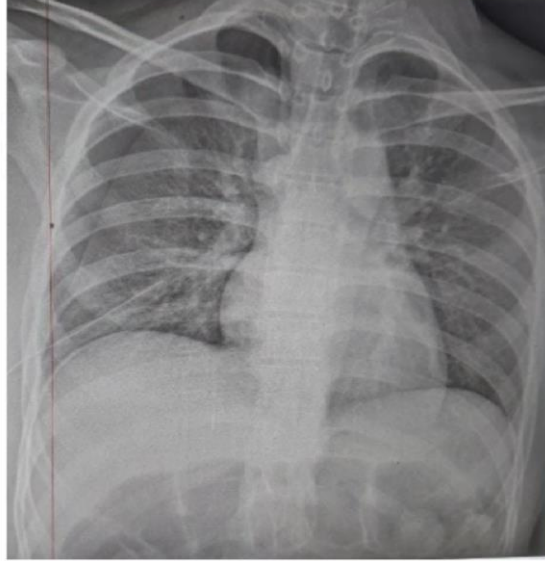


Figure 2

Figure 1. Initial chest X-ray, complete right pneumothorax. Figure 2 Control X-ray after placement of pleural tube.

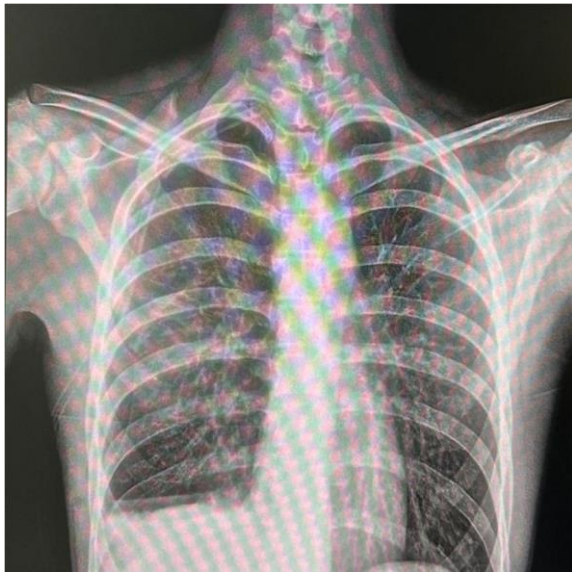

Figure 3

Figure 3. Total re-expansion of pneumothorax.

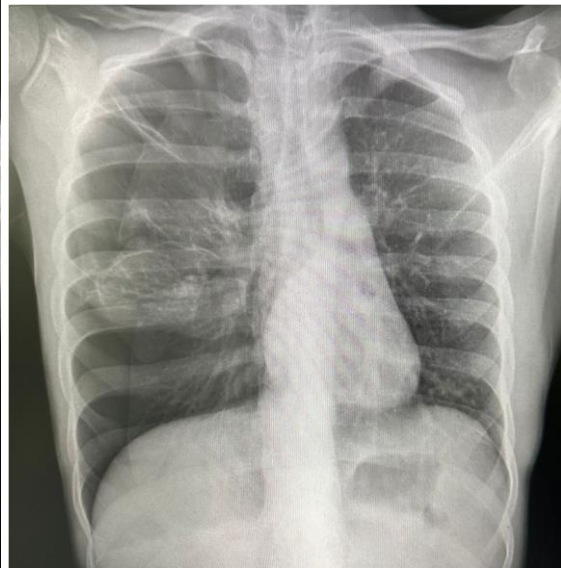


Figure 4

Figure 4. Recurrent pneumothorax

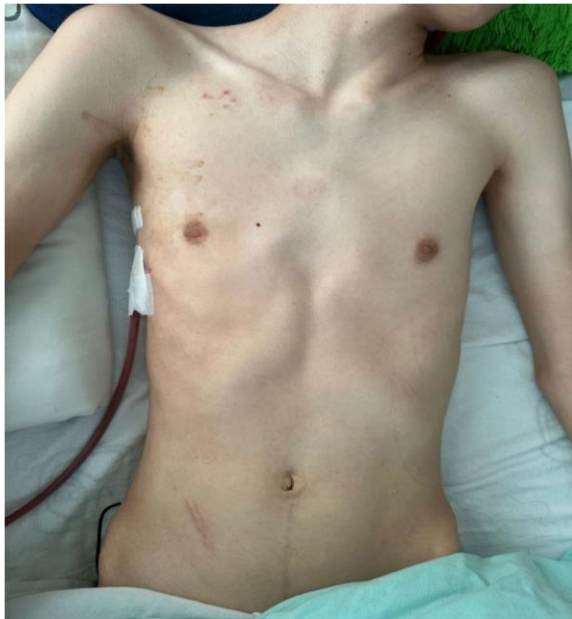

Figure 5

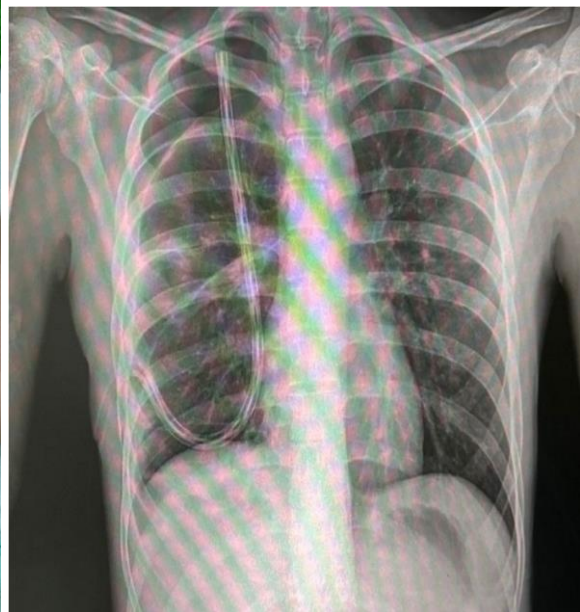

Figure 6

Figure 5. SEP repositioning showing pectus excavatum and ectomorphic complexión.

Figure 6. Control X-ray after pleurodesis.

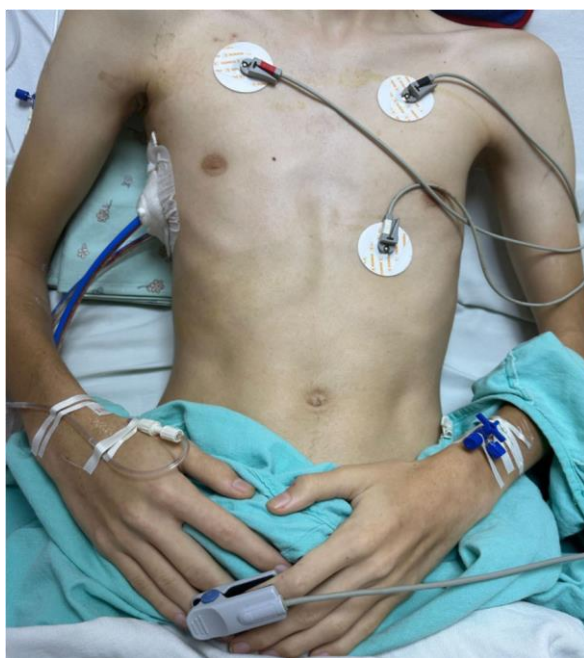

Figure 7

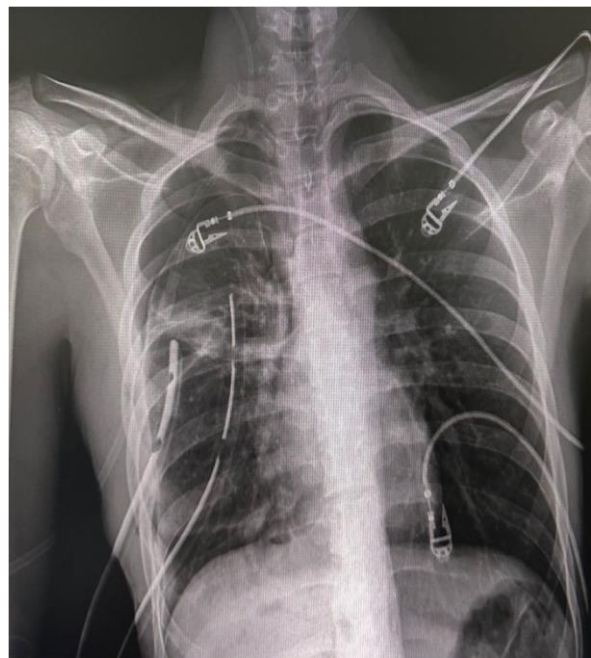

Figure 8

Figure 7. Placement of double anterior and posterior endopleural probe, arachnoidactyly.

Figure 8. Control X-ray after placement of double probe at 24 hours.

Table 1. Entities associated with secondary pneumothorax

Chronic obstructive pulmonary disease
Asthma
Cystic fibrosis
Pneumonia (e.g., necrotizing, Pneumocystis jirovecii) • Lung abscess
Lung abscess
Tuberculosis
Malignant neoplasm

Recurrent Spontaneous Pneumothorax of Unknown Etiology in a Young Patient: Case Report

Interstitial lung disease (e.g., idiopathic pulmonary fibrosis, sarcoidosis, lymphangioliomyomatosis), Connective tissue disease (e.g., Marfan syndrome, Ehlers-Danlos syndrome, rheumatoid arthritis).
Pulmonary infarction
Foreign body aspiration.
Catamenial (associated with menstruation secondary to thoracic endometriosis).
Birt-Hogg-Dube syndrome.

CONCLUSION

Spontaneous pneumothorax, in the context of a young patient with clinical characteristics such as those of our patient: tall stature, pectus excavatum, hyperlaxity of the integuments and aortic-mitral murmur, gives us high suspicion of a secondary cause, especially recurrent pneumothorax. Although Marfan syndrome can manifest in different devices and systems, the most life-threatening forms of presentation are related to cardiovascular complications; we must remember that spontaneous pneumothorax is a pulmonary manifestation strongly associated with this genetic alteration. In this case we present an example in which more than two systems are involved, so we can conclude that a good clinical history and in particular a focus on maternal-fetal history and a detailed physical examination are the most useful tools for the clinician in a hospital with limited resources to integrate a diagnosis of connective tissue diseases.

AUTHOR CONTRIBUTIONS

Conceptualization: Barragan-Lagunes Isabel, Trelles-Hernandez Daniela, Lopez-Vargas Ener Rene Rodriguez-Relingh Kim.

Data Collection: Barragan-Lagunes Isabel, Trelles-Hernandez Daniela

Research: Barragan-Lagunes Isabel, Trelles-Hernandez Daniela, Lopez-Vargas Ener Rene Rodriguez-Relingh Kim.

Methodology: Trelles-Hernandez Daniela, Rodriguez-Relingh Kim.

Project management:

Supervision: Rodriguez-Relingh Kim, Mayra

Validation: Barragan-Lagunes Isabel, Trelles-Hernandez Daniela.

Visualization: Barragan-Lagunes Isabel, Trelles-Hernandez Daniela, Rodriguez-Relingh Kim

REFERENCES

- I. Costumbrado, John and Sassan Ghassemzadeh. "Spontaneous pneumothorax." StatPearls, StatPearls Publishing, July 25, 2022.
- II. Zeigler SM, Sloan B, Jones JA. Pathophysiology and Pathogenesis of Marfan Syndrome. *Adv Exp Med Biol.* 2021;1348:185-206. doi: 10.1007/978-3-030-806149_8. PMID: 34807420; PMCID: PMC8915437.
- III. Martínez-Sebastián A. Idiopathic primary spontaneous pneumothorax in adolescents. *Rev Mex*

Pediatr. 2021; 88(1): 22-25.
<https://dx.doi.org/10.35366/99415>

- IV. Garófalo Espinel, et al (2020). Spontaneous pneumothorax, diagnosis and treatment. *RECIMUNDO*, 4(4), 300-309.

[https://doi.org/10.26820/recimundo/4.\(4\).octubre.2020.300-309](https://doi.org/10.26820/recimundo/4.(4).octubre.2020.300-309).

- V. Loeys BL, Dietz HC, Braverman AC, et al The revised Ghent nosology for the Marfan syndrome *Journal of Medical Genetics* 2010;47:476-485.

- VI. Delpy JP, et al. Surgical treatment of spontaneous pneumothorax: are there prognostic factors influencing postoperative complications? *Eur J Cardiothorac Surg.* 2016 Mar;49(3):862-7.