

## **Peritoneal Tumors of Mullerian Origin: A Case Report and Review of the Literature**

**Emmanuel Montoya Torres<sup>1</sup>, Bianca Marivi Pale Campomanes<sup>2</sup>, Vanessa Krystel Villafuerte Hernández<sup>3</sup>, Arisbel Mendoza Tello<sup>4</sup>, Arantxa Elena Cisneros Ruiz<sup>5</sup>**

<sup>1</sup>Universidad Autónoma de Sinaloa. Sinaloa, México.

<sup>2,5</sup>Universidad Veracruzana campus Xalapa. Xalapa, Veracruz, México.

<sup>3,4</sup>Universidad Michoacana de San Nicolás de Hidalgo. Michoacán, México.

### **ABSTRACT**

Primary peritoneal tumors share a common anatomical site and therefore their clinical manifestations are very similar. When peritoneal masses are detected, the tentative initial diagnosis is secondary to metastatic disease, which has been determined most frequently in the peritoneal cavity. However, primary peritoneal tumors should always be included in the differential diagnosis. Among the primary malignant peritoneal neoplasms, mesothelial tumors have been identified (malignant mesothelioma, well-differentiated papillary mesothelioma, benign cystic mesothelioma, adenomatoid tumor of the peritoneum), epithelial-type tumors (primary peritoneal serous carcinoma, primary peritoneal serous borderline tumor), tumors of the smooth muscle (disseminated peritoneal leiomyomatosis) and tumors of uncertain or undetermined origin (desmoplastic small round cell tumor, peritoneal solitary fibrous tumor).

### **ARTICLE DETAILS**

**Published On:**  
**12 November 2022**

**Available on:**  
<https://ijmscr.org/>

### **INTRODUCTION**

Primary carcinoma of the peritoneum is a pathology that has been defined relatively recently. It is characterized by an abnormal carcinomatosis of the peritoneal cavity with minimal or negative involvement of the ovarian adnexa. One of the first few cases reported in the medical literature involved a young woman with a pelvic tumor with peritoneal involvement, with characteristics of papillary serous ovarian cancer. However, it was later determined that the peritoneal tumor is a lineage of a mesothelioma, which would later be classified as a tumor of mullerian origin. Based on medical evidence, 10-15% of cases of advanced "ovarian cancer" should be reclassified as primary peritoneal carcinomas. Although there are many similarities between epithelial ovarian cancer and peritoneal carcinoma, molecular and epidemiological studies suggest that these two pathologies have certain discrepancies.<sup>1,2</sup>

This article summarizes the current literature regarding a case of a series of abdominal tumors of ovarian origin in a 32-year-old patient. In addition, the most important characteristics of primary neoplastic diseases of the peritoneum are reviewed to provide the general practitioner with a basis for the differential diagnosis between benign and malignant

processes, whether primary or secondary, which commonly present with a similar spectrum of imaging findings. . Throughout the article, we will highlight a series of clinical, epidemiological and pathological observations characteristic of these tumors, which will allow the doctor make a more specific diagnosis.<sup>1,2,3</sup>

This pathology presents with non-specific gastrointestinal symptoms and signs and it is common for the initial management to be by a general surgeon due to the presence of intestinal occlusion or data of acute abdomen. The objective of the article is to carry out a bibliographic review of the main databases in relation to advances in the diagnosis and surgical treatment of primary peritoneal cancer. Present the advances in epidemiology and pathology, clinical picture, surgical treatment and management guidelines in peritoneal cancer.<sup>4,5</sup>

### **EPIDEMIOLOGY**

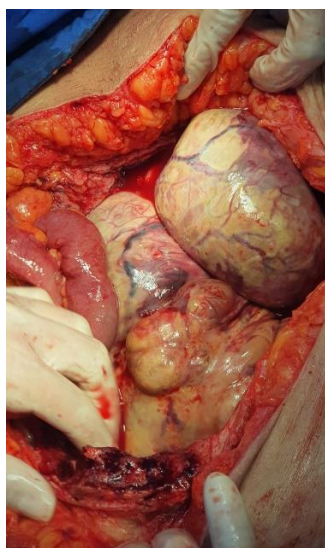
The incidence of primary carcinoma of the peritoneum is unknown, it is estimated that approximately 10% of cases diagnosed as ovarian cancer are really primary of the peritoneum. Due to the greater knowledge of this entity, there is a relative increase in frequency. It is estimated that up to

## Peritoneal Tumors of Mullerian Origin: A Case Report and Review of the Literature

18% of laparotomies performed for ovarian cancer in the final pathology report will correspond to primary peritoneal cancer. We found epidemiological differences between primary peritoneal cancer and mesothelioma. Malignant mesothelioma usually occurs in men (with incidences of 60-80%), and in more than 80% there is evidence of housing with asbestos, it has a poor response to chemotherapy and survival time is short in most cases.<sup>6,7</sup>

Primary peritoneal cancer occurs almost exclusively in women, although two cases have been reported in men and there is no history of asbestos exposure in them.<sup>8</sup>

Recent studies have focused on the epidemiological differences between primary carcinoma of the peritoneum and epithelial ovarian cancer. When it has been diagnosed, women present with an age of almost 64 years, unlike men who present with 55. As a risk factor, it has been found that women with primary cancer of the peritoneum have had an earlier menarche, more pregnancies and less history of gynecological cancers. No study has shown significant differences in relation to race, socioeconomic status, smoking, oral contraceptives or hormone replacement therapy. There is no evidence to describe whether pregnancy or the use of oral contraceptives decreases the risk of peritoneal cancer, it is also unknown whether infertility increases the risk of primary peritoneal cancer. Women with BRCA1 mutations have an increased risk of developing primary peritoneal cancer. In these women, it is estimated that the risk of developing it after prophylactic oophorectomy is approximately 5-10%. The risk for women with BRCA2 gene mutations is unknown.<sup>9,10,11</sup>



**Figure 1. Large abnormal abdominal masses**

### **PATHOLOGY**

The gross appearance of primary peritoneal carcinoma is similar to advanced stage epithelial ovarian cancer, except that the ovarian adnexa remain normal in size with minimal surface implants. Extensive tumor implants are typically

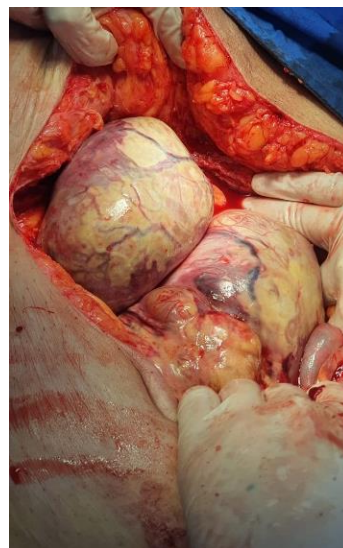
### **CLINICAL PRESENTATION**

The clinical presentation for women with primary peritoneal cancer is very similar to that of patients with advanced epithelial ovarian cancer. 75% of cases have a preoperative diagnosis of ovarian cancer, but when entering the cavity they find neoplastic masses.<sup>12,13</sup>

The most common symptoms are diffuse abdominal pain (65%), constant abdominal distention (51%), changes in bowel habit (30%), nausea/vomiting (9%), urinary frequency (6%). They are associated: abdominal distension, postprandial fullness and changes in the intestinal habit in 80% of the cases, including intestinal occlusion secondary to the mass effect generated or due to adhesions. Only 6% of cases are asymptomatic. The pelvic exam may be normal because there is minimal involvement of the ovaries and there may be a delay in diagnosis if imaging studies are not ordered in time.<sup>14,15</sup>

### **CLINICAL CASE PRESENTATION**

This is a female patient who was admitted to the emergency department due to diffuse abdominal pain, for which imaging studies were requested to rule out appendiceal pathology, finding multiple intra-abdominal masses of approximately 14x12x10 centimeters in size in the computerized axial tomography report. She was admitted to the operating room by the oncologist surgeon, finding masses adhered to deep planes in the peritoneum with significant vascular compromise, without the possibility of surgical resection, so she proceeded to close and establish chemotherapy treatment. (Figure 1) (Figure 2). Waiting for the reduction of the tumors for subsequent surgical resection.



**Figure 2. Large tumors attached to deep planes.**

found in the abdominal and pelvic peritoneum, ascites, "omental cake", diaphragmatic implants and frequent pleural effusion.<sup>16</sup>

The diagnosis must be made after a careful evaluation of the surgical piece and subsequently sent for an adequate

## Peritoneal Tumors of Mullerian Origin: A Case Report and Review of the Literature

histopathological study, initially it may be indistinguishable from epithelial ovarian cancer. In 1988, a study by Mills et al. were the first to establish the criteria to separate these two entities: normal macroscopic ovaries, size less than or equal to 3 cm, with implants on the surface and minimal invasion.<sup>17,18</sup>

### SURGICAL MANAGEMENT

Due to the clinical and pathological similarity between epithelial ovarian cancer and primary peritoneal cancer, many authors have suggested a treatment plan very similar to that used in ovarian cancer. Surgical exploration is important to establish the diagnosis and perform cytoreductive surgery and, if possible, resection. Extensive debulking is required in 98% of cases for abdominal wall tumor and pelvic disease. Because the diagnosis can only be made after histopathological study, all cases are preferably managed surgically in conjunction with gynecology and oncology, as if it were epithelial ovarian cancer. Omentectomy is performed because tumor infiltration is found in 80-100% of patients. In the case of macroscopic pelvic and para-aortic adenopathies, lymph node dissection is performed, but routine dissection is not necessary in all cases.<sup>19,20,22</sup>

### FIRST LINE CHEMOTHERAPY

Neoadjuvant therapy has been used in women with advanced ovarian cancer, or when optimal reduction cannot be ensured with surgery or radiation therapy. Neoadjuvant chemotherapy is administered to reduce tumor volume, the possibility of performing optimal cytoreduction surgery is greater and surgical morbidity decreases in addition to increasing the survival rate. Patients who respond to neoadjuvant chemotherapy undergo exploratory laparotomy in addition to performing hysterectomy, bilateral salpingo-oophorectomy, and omentectomy, because tumor activity at these sites is not completely eradicated by chemotherapy alone.<sup>23,24</sup>

Necessary judgment must be taken to take into account that, if upon inspecting the peritoneal cavity we consider that our surgery will be incomplete, and not even suboptimal, it is preferable to take a biopsy, which will allow a rapid postoperative recovery, so that the patient begins treatment with chemotherapy as soon as possible for induction and subsequent laparotomy. In such a case, the procedure should be limited to allow rapid postoperative recovery and prompt initiation of chemotherapy.<sup>25</sup>

### CONCLUSIONS

Surgery together with chemotherapy constitutes the cornerstone in the therapeutic plan against primary cancer of the peritoneum. The role of surgery from diagnosis, staging and finally as therapeutic cytoreduction, with a significant impact on survival, is not in doubt. The generalities in the diagnostic approach and basic concepts of surgical procedures in peritoneal cancer and epithelial ovarian cancer should be known, although they are different in their

pathogenesis and prognosis. The surgeon must know the importance of making a maximum surgical effort to improve patient survival. It must always be considered that this pathology can be found in a picture of intestinal sub-occlusion due to adhesions, or as an unexpected finding in emergency surgery.

### REFERENCES

- I. Levy AD, Arnaiz J, Shaw JC, Sobin LH. From the archives of the AFIP: primary peritoneal tumors: imaging features with pathologic correlation. *Radiographics*. 2008;28(2):583-607; quiz 212.
- II. McLaughlin PD, Filippone A, Maher MM. Neoplastic diseases of the peritoneum and mesentery. *AJR Am J Roentgenol*. 2013;200(5):W420-30.
- III. Raptopoulos V, Gourtsoyiannis N. Peritoneal carcinomatosis. *Eur Radiol*. 2001;11(11):2195-206.
- IV. Pickhardt PJ, Bhalla S. Primary neoplasms of peritoneal and sub-peritoneal origin: CT findings. *Radiographics*. 2005;25(4):983-95.
- V. Marin D, Catalano C, Baski M, Di Martino M, Geiger D, Di Giorgio A, et al. 64-Section multidetector row CT in the preoperative diagnosis of peritoneal carcinomatosis: correlation with histopathological findings. *Abdom Imaging*. 2010;35(6):694-700.
- VI. Siewert B, Sosna J, McNamara A, Raptopoulos V, Kruskal JB. Missed lesions at abdominal oncologic CT: lessons learned from quality assurance. *Radiographics*. 2008;28(3):623-38.
- VII. Macari M, Megibow AJ, Balthazar EJ. A pattern approach to the abnormal small bowel: observations at MDCT and CT enterography. *AJR Am J Roentgenol*. 2007;188(5):1344-55.
- VIII. Funicelli L, Travaini LL, Landoni F, Trifiro G, Bonello L, Bellomi M. Peritoneal carcinomatosis from ovarian cancer: the role of CT and [(1)(8)F]FDG-PET/CT. *Abdom Imaging*. 2010;35(6):701-7.
- IX. Metser U, You J, McSweeney S, Freeman M, Hendler A. Assessment of tumor recurrence in patients with colorectal cancer and elevated carcinoembryonic antigen level: FDG PET/CT versus contrast-enhanced 64-MDCT of the chest and abdomen. *AJR Am J Roentgenol*. 2010;194(3):76671.
- X. Anthony MP, Khong PL, Zhang J. Spectrum of (18)F-FDG PET/CT appearances in peritoneal disease. *AJR Am J Roentgenol*. 2009;193(6):W523-9.
- XI. Elsayes KM, Staveteig PT, Narra VR, Leyendecker JR, Lewis JS, Jr., Brown JJ. MRI of the peritoneum: spectrum of abnormalities. *AJR Am J Roentgenol*. 2006;186(5):1368-79.

## Peritoneal Tumors of Mullerian Origin: A Case Report and Review of the Literature

- XII. Satoh Y, Ichikawa T, Motosugi U, Kimura K, Sou H, Sano K, et al. Diagnosis of peritoneal dissemination: comparison of 18F-FDG PET/CT, diffusion-weighted MRI, and contrast-enhanced MDCT. *AJR Am J Roentgenol.* 2011;196(2):447-53.
- XIII. Kyriazi S, Collins DJ, Morgan VA, Giles SL, deSouza NM. Diffusion-weighted imaging of peritoneal disease for noninvasive staging of advanced ovarian cancer. *Radiographics.* 2010;30(5):1269-85.
- XIV. Fujii S, Matsusue E, Kanasaki Y, Kanamori Y, Nakanishi J, Sugihara S, et al. Detection of peritoneal dissemination in gynecological malignancy: evaluation by diffusion-weighted MR imaging. *Eur Radiol.* 2008;18(1):18-23.
- XV. Whittaker CS, Coady A, Culver L, Rustin G, Padwick M, Padhani AR. Diffusion-weighted MR imaging of female pelvic tumors: a pictorial review. *Radiographics.* 2009;29(3):759-74; discussion 74-8.
- XVI. Kyriazi S, Collins DJ, Messiou C, Pennert K, Davidson RL, Giles SL, et al. Metastatic ovarian and primary peritoneal cancer: assessing chemotherapy response with diffusion-weighted MR imaging--value of histogram analysis of apparent diffusion coefficients. *Radiology.* 2011;261(1):182-92.
- XVII. Oei TN, Jagannathan JP, Ramaiya N, Ros PR. Peritoneal sarcomatosis versus peritoneal carcinomatosis: imaging findings at MDCT. *AJR Am J Roentgenol.* 2010;195(3):W229-35.
- XVIII. Levy AD, Shaw JC, Sobin LH. Secondary tumors and tumorlike lesions of the peritoneal cavity: imaging features with pathologic correlation. *Radiographics.* 2009;29(2):347-73.
- XIX. Boffetta P. Epidemiology of peritoneal mesothelioma: a review. *Ann Oncol.* 2007;18(6):985-90.
- XX. Roggli VL, Sharma A, Butnor KJ, Sporn T, Vollmer RT. Malignant mesothelioma and occupational exposure to asbestos: a clinicopathological correlation of 1445 cases. *Ultrastruct Pathol.* 2002;26(2):55-65.
- XXI. Churg A. Tumors of the serosal membranes. pathology. Aaot, editor: Washington, DC: American Registry of Pathology in collaboration with the Armed Forces Institute of Pathology, 2006.; 2006.
- XXII. Society AC. Cancer Facts & Figures 2011. Atlanta, GA: American Cancer Society, 2011.
- XXIII. 23.Tavassoli FA. Pathology and genetics of tumours of the breast and female genital organs. Lyon, France: IARC; 2003.
- XXIV. Meyers M. Meyers' dynamic radiology of the abdomen: normal and pathologic anatomy. New York Springer; 2011.
- XXV. Antman K, Shemin R, Ryan L, Klegar K, Osteen R, Herman T, et al. Malignant mesothelioma: prognostic variables in a registry of 180 patients, the Dana-Farber Cancer Institute and Brigham and Women's Hospital experience over two decades, 1965-1985. *J Clin Oncol.* 1988;6(1):147-53.