International Journal of Medical Science and Clinical Research Studies

ISSN(print): 2767-8326, ISSN(online): 2767-8342

Volume 04 Issue 11 November 2024

Page No: 2143-2152

DOI: https://doi.org/10.47191/ijmscrs/v4-i11-32, Impact Factor: 7.949

A 32-Year-Old Man C-ANCA Vasculitis Having Sudden Onset Blindness Due To Non-Proliferative Retinopathy and Exudative Maculopathy Treated Successfully with Intravitreal Injection of Bevacizumab: A Rare Case Report

Khin Phyu Pyar[1], Zayar Tun[2], Tun Min Aung[3], Aung Nyan Lynn[4], Soe Win Hlaing[5], Aung Phyoe Kyaw[4] , Zar Ni Htet Aung[4], Thurein Win[4]

[1]Professor and Head/ Senior Consultant Physician and Nephrologist, Department of Medicine/Nephrology, Defence Services Medical Academy/ No. (1) Defence Services General Hospital (1000-Bedded), Yangon, Myanmar.

[2]Lecturer, Department of Ophthalmology, Defence Services Medical Academy, Myanmar.

[3]Associate Professor and Head of Department, Department of ophthalmology, Defence Services Medical Academy, Myanmar.

[4]Consultant Physician, No. (1) Defence Services General Hospital (1000-Bedded), Yangon, Myanmar.

[5]Senior Consultant Physician, No. (1) Defence Services General Hospital (1000-Bedded), Yangon, Myanmar.

ABSTRACT

The patient was a 32-year-old doctor known case of c-ANCA positive vasculitis developed sudden onset blurring vision on his left eye. Visual acuity was 6/12 right eye and 6/18 on left eye. Ophthalmic examination revealed exudative maculopathy with non-proliferative retinopathy on both eye; severe on left side. He was treated successfully with three dose of monthly intravitreal bevacizumab injections. He was on corticosteroids for pauci-immune glomerulonephritis and maintenance hemodialysis as a renal replacement therapy.

KEYWORDS: c-ANCA vasculitis, blindness, exudative maculopathy, non-proliferative retinopathy, bevacizumab

ARTICLE DETAILS

Published On:
25 November 2024

Available on:
https://ijmscr.org/

INTRODUCTION

Antineutrophil cytoplasmic antibody (ANCA)-associated vasculitis is a group of multisystem diseases that can have several ocular manifestations. Eye manifestation usually involves anterior chamber; episcleritis; scleritis; and conjunctivitis. Posterior chamber involvement is uncommon. Retinal vasculitis may result in ischemia owing to inflammation of retinal blood vessels, vascular occlusion and subsequent retinal hypoperfusion. It can cause visual loss secondary to macular ischemia, macular edema, and neovascularization leading to vitreous hemorrhage, fibrovascular proliferation, and tractional retinal detachment (Talat et al., 2014) (Aliya & T, 2021). It is extremely important to find out underlying cause producing retinal vasculitis; it is usually infective or noninfective (autoimmune). Timely treatment can save vision. Prognosis is good in early stages.

In ANCA associated vasculitis, the ocular manifestation may be due to active vasculitis, disease-associated damage, and toxicities of therapy (M. L. Junek et al., 2023) (Das et al., 2010).Therefore, it is essential to detect the cause of specific vasculitis as each has its specific treatment. This case report described blindness due to exudative maculopathy with non-proliferative retinopathy on both eyes.

CASE PRESENTATION

A 32-year-old doctor developed sudden onset blurring of vision on left eye. He was diagnosed as c-ANCA positive Wegener's Granulomatosis 6 months ago; he was on corticosteroids for pauci-immune glomerulonephritis. And, he was on maintenance hemodialysis as renal replacement therapy for 5 months. He was on multiple antihypertensive drugs to maintain blood pressure at 140/90 mmHg; nifedipine, carvedilol, indapamide, doxazosin and methyl dopa.

The patient was apyrexial; blood pressure was 140/90 mmHg; pulse rate was 80/minutes; visual acuity was 6/12 on right eye and 6/18 on left eye. Fundoscopy revealed bilateral retinal flamed shaped, dot and blot hemorrhages, and macular edema suggestive of exudative maculopathy with pre-proliferative

retinopathy on both eyes; severe on left side. Photo (1) and (2) show smartphone fundoscopy. Optical coherence tomography (OCT) macula of both eyes done on 14 June 2024 showing multiple intraretinal cystic spaces and subretinal fluid at foveal area indicating exudative macular oedema. Optical coherence tomography angiography (OCT-A) of both eyes done on 14 June 2024 showing normal foveal avascular zone (FAZ) and absence of capillary non-perfusion area with abnormally perifoveal dilated and tortuous capillary vessels indicating a sign of retinal vasculitis. They are illustrated in photos (5, 6, 7 & 8).

At the time of visual problem, there was no clinical evidence of active vasculitis; no vasculitis rash; no arthralgia; no fever; ESR was not high. The titer of c-ANCA could not be done as we were in low resource setting.

Blood tests were normal except anemia; hemoglobin was 8.3 gm% (normochromic normocytic); Total WBC count was $6.4X10^9$/L; platelet count was $170X10^9$/L; CRP was normal. The cause of anemia was due to anemia of chronic disease and end stage renal disease. Although he was on low dose maintenance corticosteroid therapy, there was no evidence of diabetes mellitus; HbA1C was normal; random blood sugar was normal.

He was treated successfully with three dose of intravitreal anti-VEGF monthly injection; first time injection intravitreal (Avastin) bevacizumab was given to both eyes on 20 June 2024. Second time on 18 July 2024; and, third time on 15 August 2024. Improvements in fundoscopy are demonstrate in photo (3) and (4). Changes in optical coherence tomography (OCT) illustrate in photo (9) & (10) . Optical coherence tomography angiography (OCT-A) features are seen in photo (11) & (12). The visual acuity of both eyes was dramatically improved up to Snellen acuity 6/6 unaided.

DISCUSSION

Antineutrophil cytoplasmic antibody (ANCA)-associated vasculitis is a group of multisystem diseases that can have several ocular manifestations. Ocular manifestations were more common at onset of disease (Pakrou et al., 2006). In this case, visual problem developed 6 months after initial diagnosis. He did receive aggressive immunosuppressive therapy for rapidly progressive c-ANCA positive crescentic pauci-immune glomerulonephritis; corticosteroids, cyclophosphamide and rituximab. As renal function deteriorated rapidly, he was on maintenance hemodialysis for 6 months. The onset of eye problem 6 months after systemic manifestation was uncommon; one reason for case reporting. The most common disease-related manifestations in ANCA associated vasculitis were reported as conjunctivitis/episcleritis and scleritis (M. Junek et al., 2022) (Carreño & Olivas-Vergara, 2023) (Alrashidi et al., 2013); even, some report mentioned as ANCA scleritis (Hoang et al., 2008). The most common ocular complications and/or damage seen were cataracts and visual impairment . Posterior chamber involvement or retinopathy were uncommon (Marcus et al., 1995). Retinal vasculitis and proliferative retinopathy was rarely found in Churg–Strauss syndrome (Cackett & Singh, 2006) and systemic sclerosis (Zhioua Braham et al., 2024). Therefore, this case report is one of the rare case.

In ANCA associated vasculitis, the ocular manifestation may be due to active vasculitis, disease-associated damage, and toxicities of therapy (M. L. Junek et al., 2023)(Das et al., 2010). In this patient, there was no evidence of active vasculitis at the time of eye problem; no fever; no polyarthralgia; no myalgia; no vasculitic rash. Both HbA1C and blood glucose monitoring were normal though he was on low dose corticosteroids; therefore, non-proliferative retinopathy could not be explained by toxicities of therapy. Therefore, bilateral non-proliferative retinopathy in this patient may be due to disease-associated damage.

The patient's vision improved gradually even after first dose of intravitreal bevacizumab injection. The visual improvement in this patient was solely due to intravitreal bevacizumab. His vision was nearly normal after 2 months. Optical coherence tomography (OCT) macula revealed exudative macular oedema indicating increased vascular permeability condition. OCT-A showed normal foveal avascular zone (FAZ) and absence of capillary non-perfusion area with abnormally dilated and tortuous perifoveal capillary vessels. All features mentioned absence of retinal ischemia and neovascularization though the evidence of retinal vasculitis persisted. The patient's vision improved nearly normal after first injection; therefore, it indicated that the disease was still mild allowing for a good response to treatment. It again highlighted the importance of early diagnosis and prompt treatment in restoring vision.

The role of fundoscopy was extremely crucial in this patient as features of exudative maculopathy and retinopathy was clearly seen. Fundus camera was currently not functioning in our hospital; therefore, fundus photos were taken using smartphone and 20 diopter condensing-lens. This smartphone fundoscopy technique was comparatively cheap, portable and easy to use. Therefore, this technique was suitable for low-income countries. This is another reason for sharing usefulness of smartphone and 20 diopter condensing-lens in ophthalmology.

Optical coherence tomography angiography (OCT-A) demonstrated the differences in retinal thickness and retinal superficial vascular density. Li et al showed reduction in retinal thickness and retinal superficial vascular density in patients with ANCA-associated vasculitis compared to healthy subjects. They suggested OCT-A for the evaluation of ANCA-associated vasculitis related ocular lesions and monitoring of disease progression (Li et al., 2024). Awareness of ocular presentation by his treating physician was important and a multidisciplinary team management was essential (D'Aquila & John, 2022).

ANCA-associated vasculitis commonly involved retinal vessels. Retinal vasculitis is characterized by inflammatory involvement of retinal arterioles, venules and/or capillaries and can be associated with a myriad of systemic and ophthalmic diseases (Agarwal et al., 2022). In short, retinal vasculitis means the inflammation of various retinal vessels. Retinal vasculitis is a sight-threatening inflammatory eye condition that involves the retinal vessels. Detection of retinal vasculitis is made clinically, and confirmed with the help of fundus fluorescein angiography, Oct and OCT-A. Retinal vasculitis is a diagnosis of inflammatory changes of the retinal arteries and/or veins consisting of vascular sheathing, vitreous cells, cotton-wool spots, and intraretinal hemorrhages. It is a sight-threatening disease due to complications from macular edema, vascular occlusion, retinal ischemia, and neovascularization.

Etiologies of retinal vasculitis include infectious and noninfectious in etiology (autoimmune/inflammatory/neoplastic); the pathogenesis and treatment are different (Ku et al., 2012). Active vascular disease is characterized by exudates around retinal vessels resulting in white sheathing or cuffing of the affected vessels (Abu El-Asrar et al., 2009). Noninfectious retinal vasculitis can be due to type-III hypersensitivity reactions, increased expression of intracellular adhesion molecules, and genetic susceptibility. Noninfectious retinal vasculitis is primarily classified on the basis of the type of retinal vessels involved. It can be further classified as an occlusive or nonocclusive. Retinal vasculitis can be a major association of systemic diseases like Behcet's disease, sarcoidosis and systemic lupus erythematosus.

Generally, effective treatment of noninfectious retinal vasculitis requires anti-inflammatory and immunosuppressive therapy. However, its specific cause for eye like active vasculitis, disease-associated damage, and toxicities of therapy must be identified first. The patients may require treatment with high-dose corticosteroids and biological agents if the cause is active vasculitis. If it is due to toxicities of therapy, either dose reduction or changing to another drug should be considered. This patient was due to disease-associated damage; he recovered with same dose of corticosteroids and intra-vitreal injection. From ophthalmologist's side, intravitreal injection of bevacizumab is used to treat neovascularization secondary to noninfective vasculitis. It should be timed with retinal laser photocoagulation to prevent further progression of retinal ischemia. Antitumor necrosis factor agents and anti-vascular endothelial growth factor injections and laser photocoagulation may be indicated to treat the occlusive disease according to Menia et al (Menia et al., 2024).

Prompt treatment of retinal vasculitis may prevent complications like vitreous hemorrhage, neovascular glaucoma, and tractional retinal detachment. This patient's vision improved gradually after first injection; he did not develop complication. Nephrologists, general physicians, rheumatologists, hematologists and ophthalmologists did a multidisciplinary approach in this patient; it was a success made by team. A targeted and individualized patient management by multidisciplinary team based treatment was recommended by Farrah et al (Farrah et al., 2019).

In this patient, there was exudative maculopathy with retinal vasculitis at the time of visual complaint. The ophthalmic assessment done 3 months ago was normal; however, OCT-A was not done as fundoscopy was normal. Triggianese et al suggested that subclinical microvascular retinal changes could be seen with OCT-A; it could detect vascular damage early (Triggianese et al., 2023). If OCT-A was done 3 months ago, vascular abnormality would have been seen. This is another learning point from this patient.

Moreover, Ozdal et al recommended multimodal imaging of the choroid for early detection of choroidal involvement in these cases. It also had prognostic implications in these life-threatening diseases (Özdal & Tugal-Tutkun, 2022).

CONCLUSION

ANCA-associated vasculitis has multi organ involvement including the eyes. Retinal vaculitis is a sight-threatening inflammatory eye condition that involves the retinal vessels. In ANCA-associated vasculitis, the specific cause of ocular manifestation must be assessed carefully because systemic treatment depends on specific pathology; active vasculitis, disease-associated damage, and toxicities of therapy. Because of the severity and potential life-threatening nature of these diseases, knowledge of the ocular manifestations is mandatory not only for the ophthalmologists but also for physicians.

ACKNOWLEDGEMENTS

The authors would like to thank the patient for giving consent to this article. Also, to all doctors and nursing team for making great efforts in caring him. The authors acknowledged Professor Myint Zaw, Professor Kyaw Zay Ya and Professor Ko Ko Lwin for administrative support.

DECLARATION OF CONFLICT OF INTEREST

The authors declared no potential conflicts of interests with respect to authorship and publication of this article.

ETHICAL APPROVAL

Our institution does not require ethical approval for reporting cases.

FUNDING

The authors received no financial support for publication of this article.

INFORMED CONSENT

The informed consent for publication in this article was obtained from patient.

REFERENCES

I. Abu El-Asrar, A. M., Herbort, C. P., & Tabbara, K. F. (2009). Differential diagnosis of retinal vasculitis. *Middle East African Journal of Ophthalmology*, *16*(4), 202–218. https://doi.org/10.4103/0974-9233.58423

II. Agarwal, A., Rübsam, A., Zur Bonsen, L., Pichi, F., Neri, P., & Pleyer, U. (2022). A Comprehensive Update on Retinal Vasculitis: Etiologies, Manifestations and Treatments. *Journal of Clinical Medicine*, *11*(9). https://doi.org/10.3390/jcm11092525

III. Aliya, S., & T, S. (2021). Retinal vasculitis – Clinical manifestations and outcome at tertiary eye care centre in south India. *Indian Journal of Clinical and Experimental Ophthalmology*, *2021*, 14883. https://doi.org/10.18231/j.ijceo.2021.111

IV. Alrashidi, S., Yousef, Y., & Krema, H. (2013). Visual loss from scleritis in C-ANCA-positive microscopic polyangiitis. *BMJ Case Reports*, *2013*. https://doi.org/10.1136/bcr-2013-009583

V. Cackett, P., & Singh, J. (2006). Churg–Strauss syndrome in association with proliferative retinopathy. *Eye*, *20*(3), 394–396. https://doi.org/10.1038/sj.eye.6701871

VI. Carreño, E., & Olivas-Vergara, O. M. (2023). Systemic Vasculitis and Its Association with the Eye. *Ophthalmologica*, *246*(3–4), 174–180. https://doi.org/10.1159/000531395

VII. D'Aquila, M. L., & John, V. J. (2022). Granulomatosis With Polyangiitis Presenting as Occlusive Retinal Vasculitis. *Journal of VitreoRetinal Diseases*, *6*(6), 467–469. https://doi.org/10.1177/24741264221076358

VIII. Das, T., Pathengay, A., Hussain, N., & Biswas, J. (2010). Eales' disease: Diagnosis and management. *Eye*, *24*(3), 472–482. https://doi.org/10.1038/eye.2009.315

IX. Farrah, T. E., Basu, N., Dweck, M., Calcagno, C., Fayad, Z. A., & Dhaun, N. (2019). Advances in Therapies and Imaging for Systemic Vasculitis. *Arteriosclerosis, Thrombosis, and Vascular Biology*, *39*(8), 1520–1541. https://doi.org/10.1161/ATVBAHA.118.310957

X. Hoang, L. T., Lim, L. L., Vaillant, B., Choi, D., & Rosenbaum, J. T. (2008). Antineutrophil Cytoplasmic Antibody–Associated Active Scleritis. *Archives of Ophthalmology*, *126*(5), 651–655. https://doi.org/10.1001/archopht.126.5.651

XI. Junek, M. L., Zhao, L., Garner, S., Cuthbertson, D., Pagnoux, C., Koening, C. L., Langford, C. A., McAlear, C. A., Monach, P. A., Moreland, L. W., Rhee, R. L., Seo, P., Specks, U., Sreih, A. G., Warrington, K., Wechsler, M. E., Merkel, P. A., & Khalidi, N. A. (2023). Ocular manifestations of ANCA-associated vasculitis. *Rheumatology (Oxford, England)*, *62*(7), 2517–2524. https://doi.org/10.1093/rheumatology/keac663

XII. Junek, M., Zhao, L., Garner, S., Cuthbertson, D., Pagnoux, C., Koening, C., Langford, C., McAlear, C., Monach, P., Moreland, L., Rhee, R., Seo, P., Specks, U., Sreih, A., Warrington, K., Wechsler, M., Merkel, P., & Khalidi, N. (2022). Ocular manifestations of ANCA-associated vasculitis. *Rheumatology*, *62*. https://doi.org/10.1093/rheumatology/keac663

XIII. Ku, J. H., Ali, A., Suhler, E. B., Choi, D., & Rosenbaum, J. T. (2012). Characteristics and Visual Outcome of Patients With Retinal Vasculitis. *Archives of Ophthalmology*, *130*(10), 1261–1266. https://doi.org/10.1001/archophthalmol.2012.1596

XIV. Li, Z.-Y., Kang, M., Qian, X.-Z., Peng, R., Hong, Q., Ying, P., Huang, H., Wang, X.-Y., Zeng, Y.-M., Hu, J.-Y., Chen, X., Wu, R., Shao, Y., & Yu, S.-J. (2024). Retinal thickness and microvascular alterations observed by optical coherence tomography in antineutrophil cytoplasmic antibody-associated vasculitis: A cross-sectional study. *2024*, *14*(7), 4998–5011.

XV. Marcus, D. M., Frederick, A. R., Raizman, M. B., & Shore, J. W. (1995). Choroidal and Retinal Detachment in Antineutrophil Cytoplasmic Antibody-Positive Scleritis. *American Journal of Ophthalmology*, *119*(4), 517–519. https://doi.org/10.1016/S0002-9394(14)71243-7

XVI. Menia, N. K., Alcibahy, Y., Pichi, F., Neri, P., & Agarwal, A. (2024). An Update on Noninfectious Retinal Vasculitis. *Ophthalmologica*, *247*(3), 133–146. https://doi.org/10.1159/000539608

XVII. Özdal, P. Ç., & Tugal-Tutkun, I. (2022). Choroidal involvement in systemic vasculitis: A systematic review. *Journal of Ophthalmic Inflammation and Infection*, *12*(1), 14. https://doi.org/10.1186/s12348-022-00292-4

XVIII. Pakrou, N., Selva, D., & Leibovitch, I. (2006). Wegener's granulomatosis: Ophthalmic manifestations and management. *Seminars in Arthritis and Rheumatism*, *35*(5), 284–292. https://doi.org/10.1016/j.semarthrit.2005.12.003

XIX. Talat, L., Lightman, S., & Tomkins-Netzer, O. (2014). Ischemic Retinal Vasculitis and Its Management. *Journal of Ophthalmology*, *2014*(1), 197675. https://doi.org/10.1155/2014/197675

XX. Triggianese, P., D'Antonio, A., Nesi, C., Kroegler, B., Di Marino, M., Conigliaro, P., Modica, S., Greco, E., Nucci, C., Bergamini, A., Chimenti, M., & Cesareo, M. (2023). Subclinical microvascular changes in ANCA-vasculitides: The role of optical coherence tomography angiography and nailfold capillaroscopy in the detection of disease-related damage. *Orphanet Journal of Rare Diseases*, *18*(1), 184. https://doi.org/10.1186/s13023-023-02782-7

XXI. Zhioua Braham, I., Boukari, M., Mokrani, M., Errais, K., Mili, I., & Zhioua, R. (2024). Multimodal imaging of bilateral occlusive retinal vasculitis and proliferative retinopathy in systemic sclerosis. *Journal Français d'Ophtalmologie*, *47*(1), 103932. https://doi.org/10.1016/j.jfo.2023.08.003

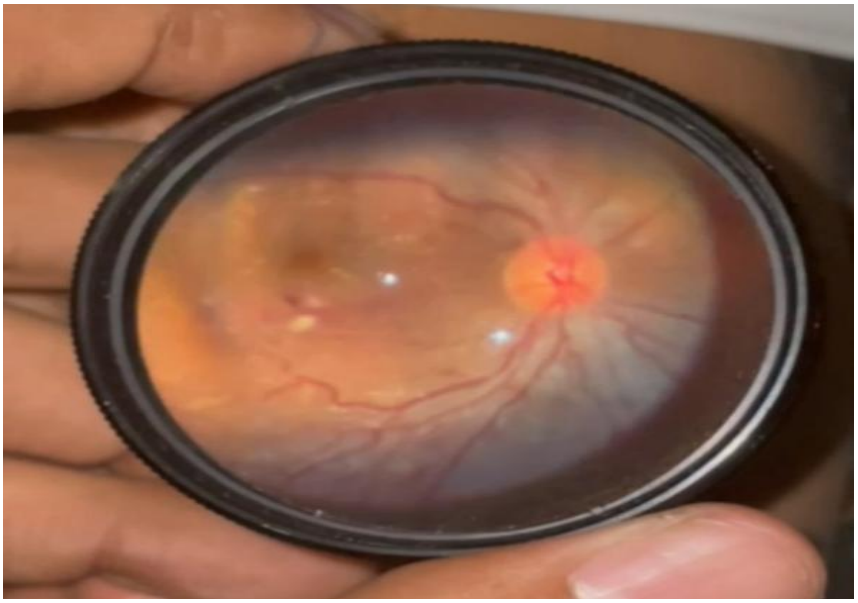

Photo (1) Smartphone Fundoscopy of right eye done on 14 June, 2024 showing multiple retinal hemorrhage and cotton wool spots at posterior pole

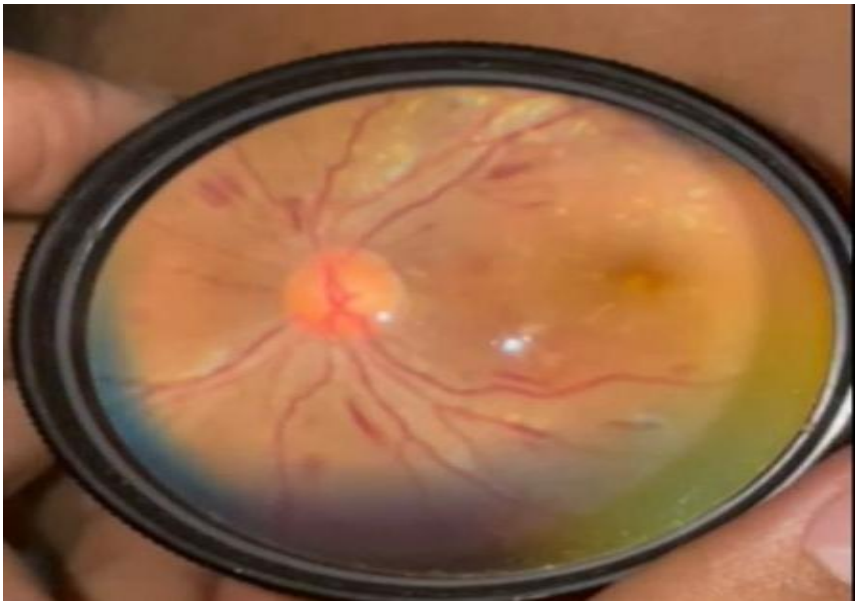

Photo (2) Smartphone fundoscopy of left eye done on 14 June, 2024 showing multiple retinal hemorrhage and hard exudate at posterior pole

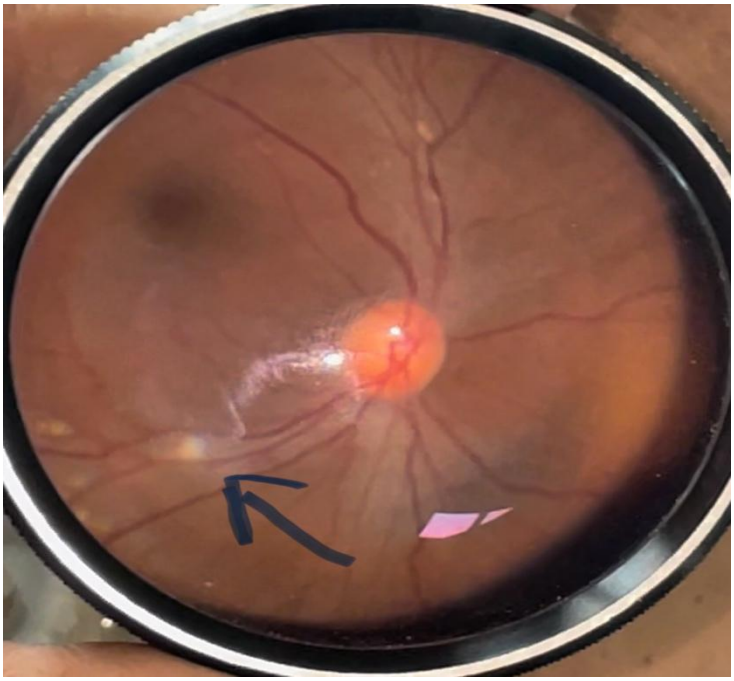

Photo (3) Smartphone fundoscopy of right eye after intravitreal bevacizumab injection showing resolving exudative maculopathy and retinal hemorrhage

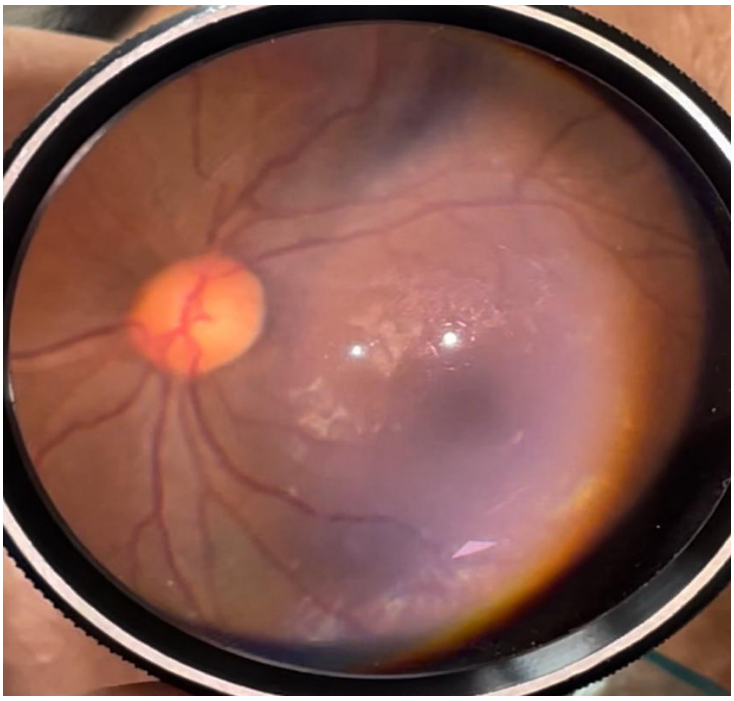

Photo (4) Smartphone fundoscopy of left eye after intravitreal bevacizumab injection showing resolving exudative maculopathy and retinal hemorrhage

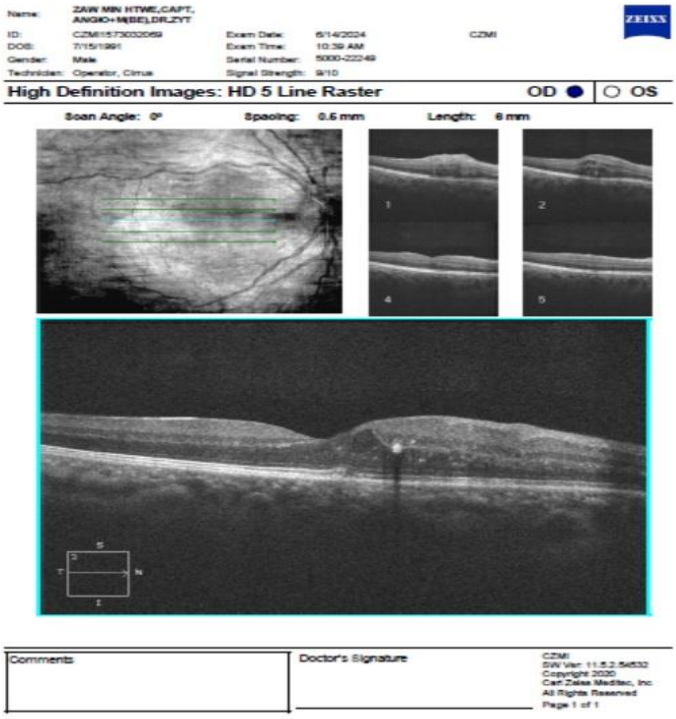

Photo (5) Optical coherence tomography macula of right eye done on 14 June 2024 showing intraretinal cystic space and exudate indicating exudative macular oedema

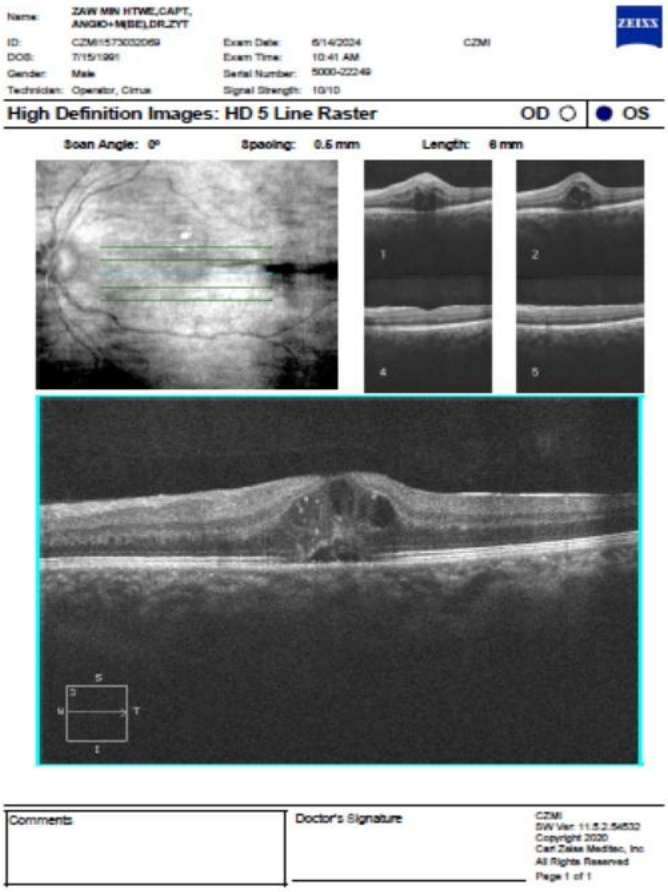

Photo (6) Optical coherence tomography macula of left eye done on 14 June 2024 showing multiple intraretinal cystic spaces and subretinal fluid at foveal area indicating exudative macular oedema

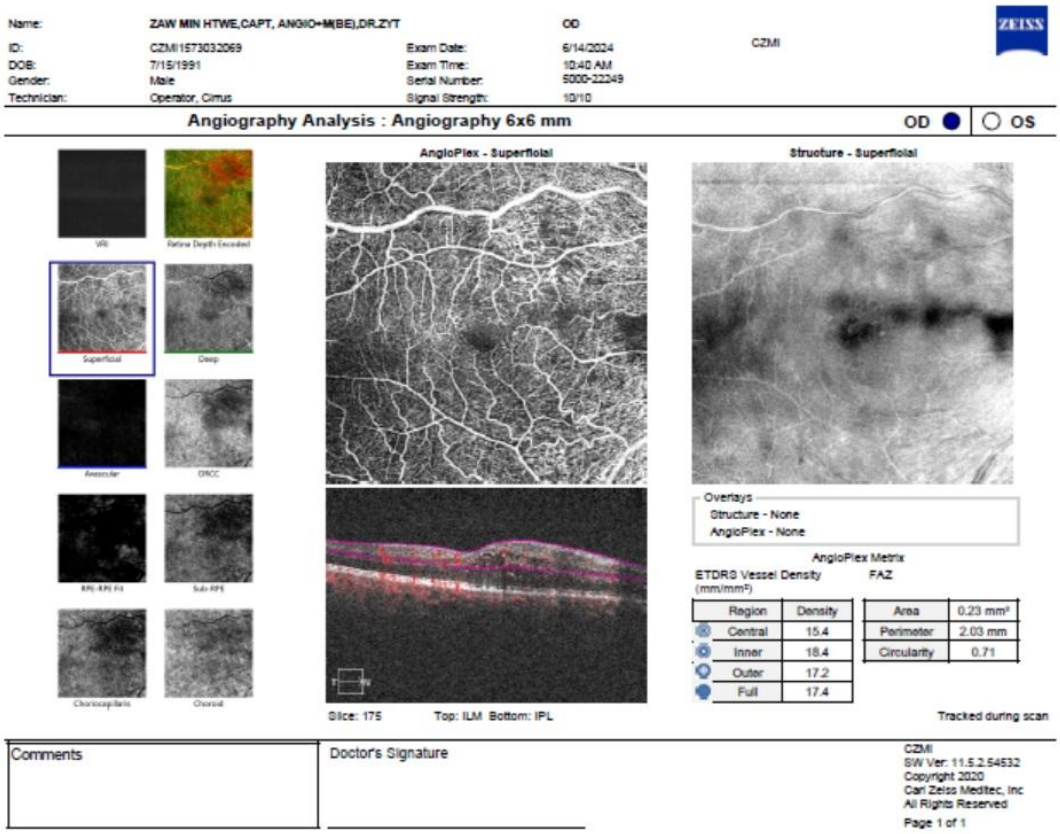

Photo (7) Optical coherence tomography angiography of right eye done on 14 June 2024 showing normal foveal avascular zone (FAZ) and absence of capillary non-perfusion area with abnormally dilated and tortuous parafoveal vessels

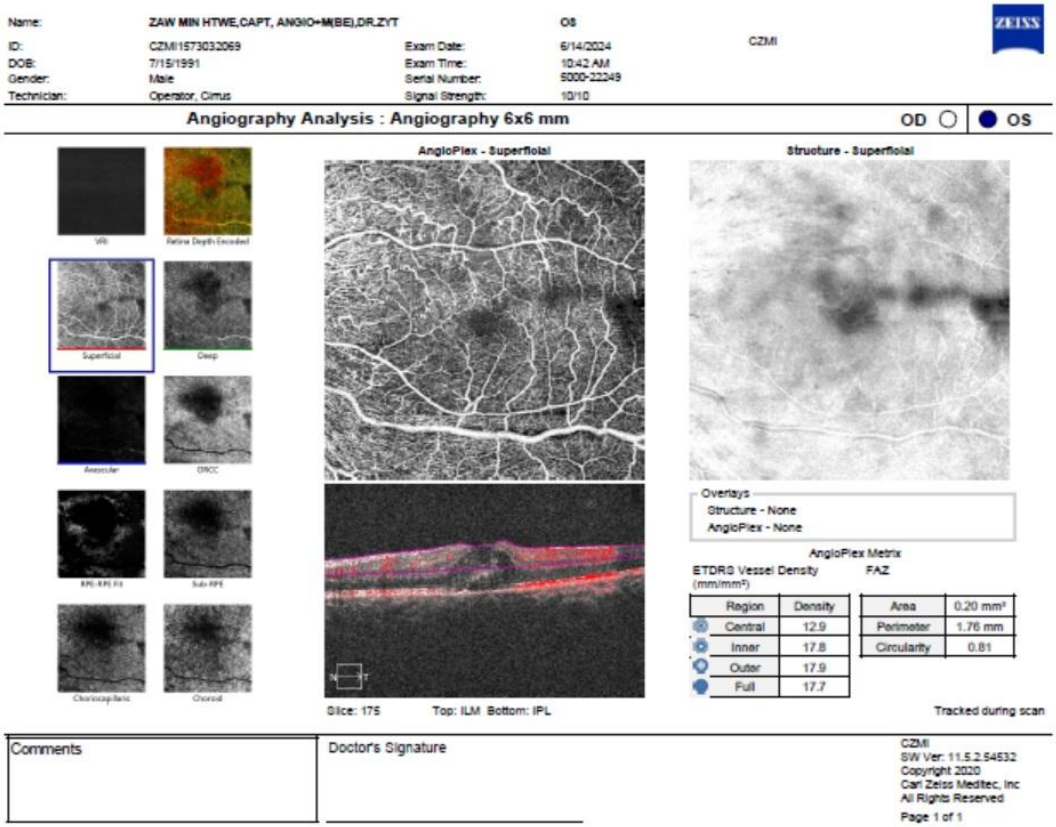

Photo (8) Optical coherence tomography angiography of left eye done on 14 June 2024 showing normal foveal avascular zone (FAZ) and absence of capillary non-perfusion area with abnormally dilated and tortuous parafoveal vessels

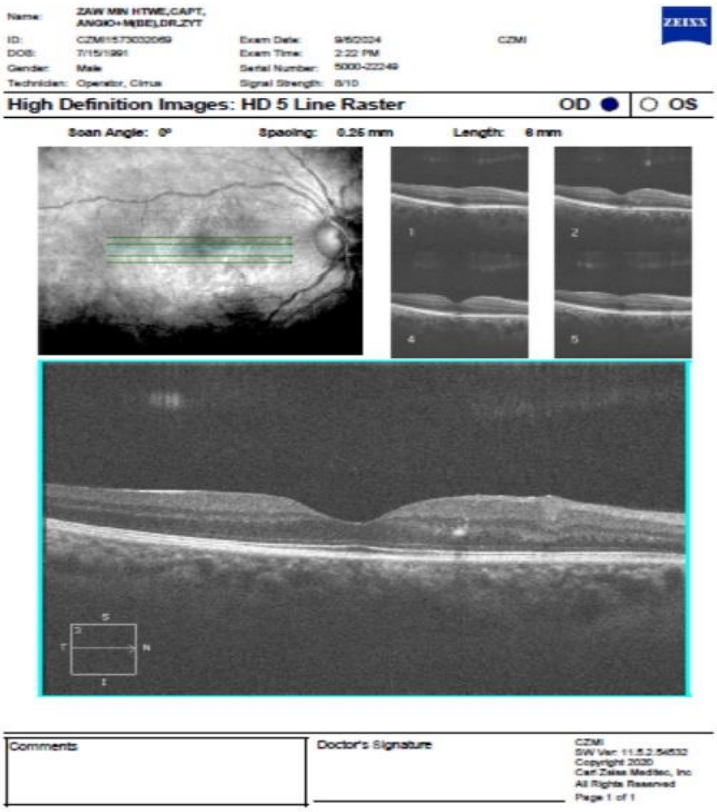

Photo (9) Optical coherence tomography macula right eye done on 9 June 2024 showing resolving macular oedema after three dose of monthly intravitreal bevacizumab injection

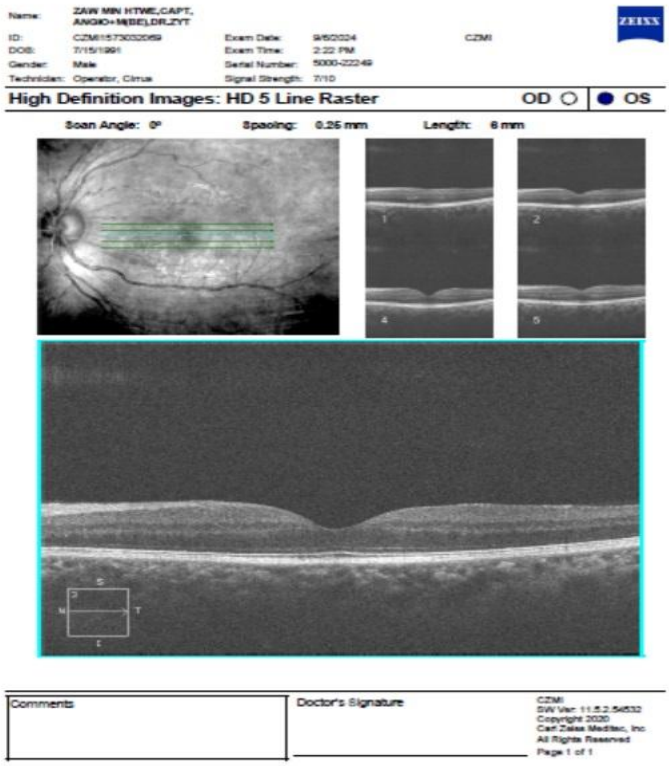

Photo (10) Optical coherence tomography macula left eye done on 9 June 2024 showing resolving macular oedema after three dose of monthly intravitreal bevacizumab injection

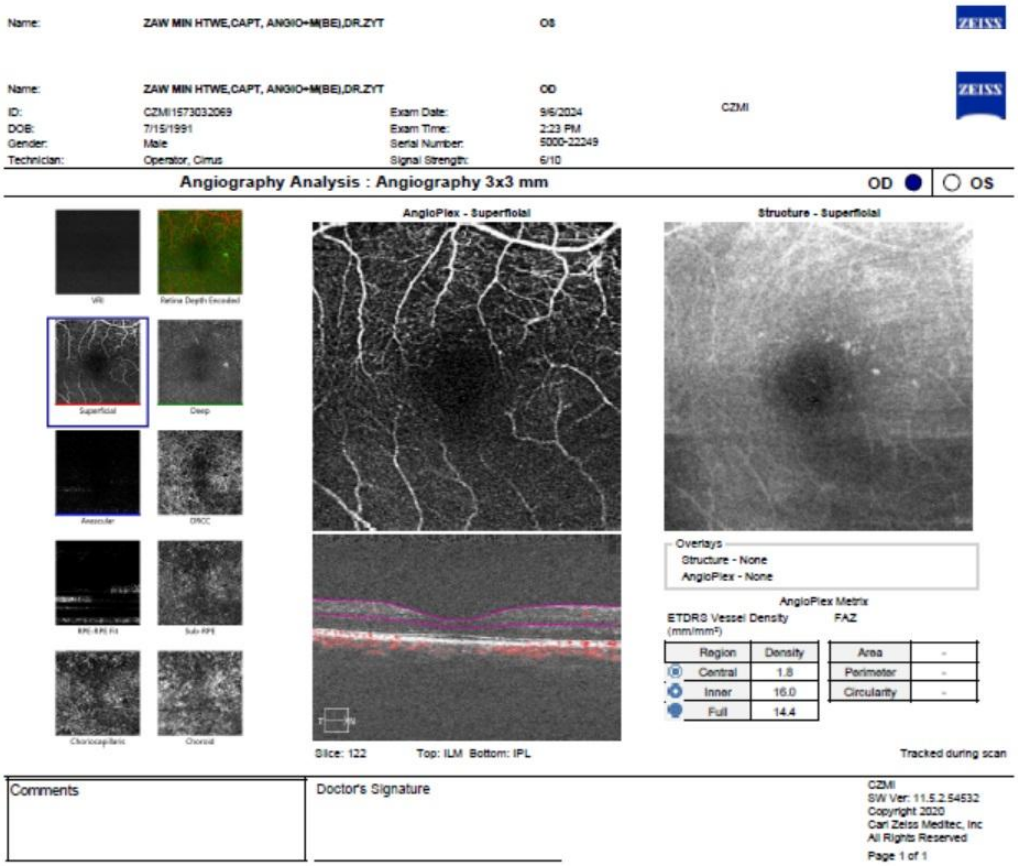

Photo (11) Optical coherence tomography angiography of right eye done on 6 September 2024 showing regression of abnormally dilated and tortuous parafoveal vessels

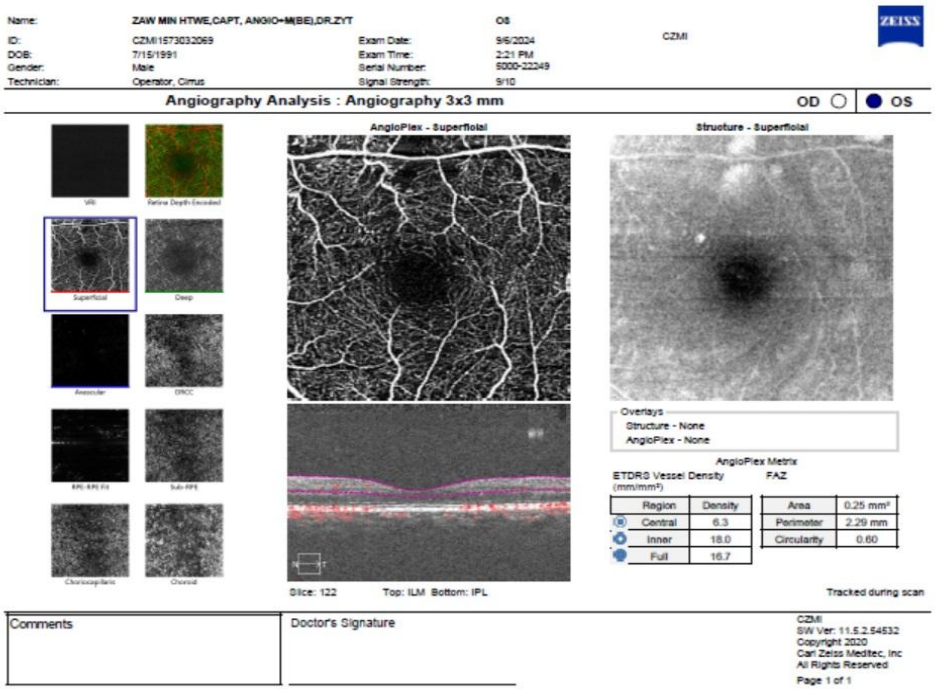

Photo (12) Optical coherence tomography angiography of right eye done on 6 September 2024 showing regression of abnormally dilated and tortuous parafoveal vessels